Syda Productions/Shutterstock

# WOULD YOU KNOW WHAT TO DO WITH AN ADVERSE EVENT?

## Dr. Patrick Treacy discusses addressing dermal filler complications

Soft tissue augmentation with temporary dermal fillers is a fast-expanding field that has become an integral part of many aesthetic practices. According to the American Academy of Aesthetic Plastic Surgeons, almost 2.5 million people received hyaluronic acid (HA) injections from plastic surgeons in 2016, making it the second most popularly performed non-surgical cosmetic procedure. These filler products are mostly safe, having a known incidence of mild and transient adverse events, but serious complications can also occur, causing gross biofilm reactions or vascular embolism, causing severe skin necrosis or even blindness.

At present, there's a paucity of literature regarding both the prevention and management of serious events, even though these complications are the very things that patients and physicians both continually fear. Many physicians, (including myself), feel that 'corporate' prefer not to address these issues and they are driven underground. Over the years, many of my colleagues have referred me their more serious problems and I consequently have developed a certain experience in this area. This insight into complications of dermal filler use will serve to highlight both of these problems and try to help one manage these complications if they should ever happen to you.

### The size of the problem

Fortunately, most adverse reactions are mild and transient. Adverse events can be grouped into expected procedure-related events, such as bruising, erythema, and tenderness; events potentially related to improper technique, such as nodule formation; and reactions to the product, such as granuloma formation.

We had a serious problem in both the UK and Ireland some years ago, with 168 different fillers being used in this marketplace. In comparison, the USA had effectively just three or four, which had been passed by the Food and Drug Administration. Things are thankfully much better in Europe now, since most of the fillers that have survived the passage of time here, are ironically the exact same ones that were passed for clinical use in the USA. This also raises the question of whether we really require a similar vetting procedure regarding the safety of filler products in this jurisdiction.

Many minor side effects, like swelling, can easily be controlled by use of oral steroids. Bruising effects are mostly due to patients taking supplements including vitamin E or omega fish oils, aspirin, Lipitor or antidepressants prior to procedure.

Moderate problems of dermal fillers are usually due to delayed onset nodules resulting in granuloma formation, inflammation and immune response.

More serious adverse reactions include biofilm and vascular embolism leading to skin necrosis or blindness.

### Why are these problems occurring?

There are many contributing factors. The first is that a questionable government policy is driving sales as more people are being allowed to inject and consequently the amount of product being used is increasing. The second is the continual introduction of new compounds and pharmaceuticals into our dermal fillers. The hyaluronic acid fillers started off as fairly simple structures, but in recent years the addition of butanediol diglycidyl ethers (BDDEs) altered the chains and now different HA dermal fillers exist for different positions in the face, and consequently we have seen quite an increase in problems.

Through the years, my experience of these higher molecular weight hyaluronic acids (Restylane® SubQ, Juvéderm® Voluma, Restylane® Macrolane) is that they have tended to be problematic in terms of delayed onset nodules. I have long advised that Radiesse® should not be injected in the perioral area or the vermillion border of the lips, and question it's use in the periocular area when we have other safer compounds to use.

Bio-Alcamid™ has long been a problem compound and I have treated many patients with the desire to remove this innocuous material from their face. It almost became the gold standard for treating patients with HIV lipodystrophy - in the days before less problematic antiretroviral drugs, when physicians had only Sculptra® as an alternative. Luckily enough for most of the HIV lipoatrophy patients that I've treated, it comes out quite easily, because you can nick it, but unfortunately it does form abscesses up to ten years later. I also noticed that many patients who removed this compound tend to stay aesthetically normal because it has formed a collagen type capsulation to occupy the area where it was placed.

## Lidocaine dangers

I'm not an advocate of lidocaine being included in every filler. This was largely done without our blessing often to aid professionals other than doctors, and I'm certainly not being territorial about this. In my mind, lidocaine is possibly a dangerous drug to be unquestionably adding to dermal filler, because of its potential to cause vasodilation.

By using it widely and without proper recourse to its effects, we're most probably setting up the arterial facial vessels like ducks in a row to be damaged by needles used by the unwary. I don't remember seeing this level of complications prior to the widespread use of lidocaine, so whilst I can't scientifically confirm it's to blame, it's definitely something we now should be considering and looking for an alternative. Local anaesthetics include varying levels of vasodilation and another one should possibly be considered. If we used lidocaine and adrenaline, the vessels would get smaller and they would be less easy to hit. For an ischemic event, you certainly don't want adrenaline on board, but adrenaline only has an effect for about eight minutes, whereas lidocaine has an effect certainly in the region of two to four hours.

## Biofilm

I have had several patients present to me with biofilm in recent years and have been able to successfully reverse these patients with Hyalase™, dexamethasone and in one instance 5-fluorouracil within three to four weeks.

I have my own theories on the etiology of biofilm. Primarily, I feel some of these biofilms are possibly mycobacteria. We like to think that the age of mycobacteria is long gone but it's not - these organisms are present in many different environments around us, including in our water supply. We know that these specialist micro-organisms tend to form colonies, if not sub-colonies and we also know that ordinary antibiotics are largely ineffective in treating them.

We know that when we take sterile cultures from biofilms, we usually grow nothing. However, if you can test for mycobacteria, quite a number of them are positive. You need to do a special PC test for mycobacteria and in the absence of this facility you'll probably miss it. Hence, I would advocate starting the patient on rifampicin and isoniazid as well as clindamycin. Biofilm is emerging more and more with the BDDE added to the hyaluronic acid and lidocaine fillers (HLAs), and consequently, these colonies actually migrate and form problems in other areas.

When dealing with a colony of biofilm, three things need to be dealt with: The HLA in the middle; the collagen capsule around it; and the bacterial colonisation. I suggest that as many as maybe 10-20% of them are mycobacterium. I advocate using Hyalase™ (Hyaluronidase) to deal with the hyaluronic acid, dexamethasone to deal with the collagen, and antibiotics to deal with the infective commensals colonising the structure. One can't be done without the other and if you give intra-lesional steroids alone, you're probably creating a problem because you're reducing the patient's local immunity, and the infection will remain.

## What is the exact mechanism of vascular problems?

While it is widely accepted that serious vascular compromise is caused by embolisation of filler material into part of the facial artery, I have dealt with some cases where the patient showed no clinical evidence of vascular compromise during injection; but presented some hours later with marked reticulation. I surmise that these patients may have sustained some venous compression due to hyaluronic acid swelling and consider the use of intravenous steroids in these patients.

Vein illumination with AccuVein® vein visualisation technology is a new technology that may reduce vascular embolic events by simply holding the device above the skin, and the vessels below are displayed on the surface of the skin. It is easy to use, and these vein finders may save valuable time for practitioners less familiar with facial anatomy.

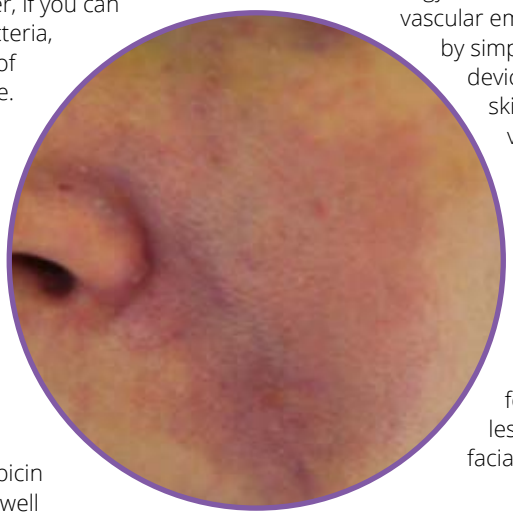

Dr. Patrick Treacy, Ailesbury Clinic, Dublin.

## Hose-pipe theory

The hose-pipe theory hypothesises that all vascular problems with dermal fillers resulting in skin necrosis or blindness are due to direct embolisation of the facial or temporal arteries or their collateral branches. Many physicians state the venous part of the system is not involved, because if you place a finger on the arterial system it will keep pulsing and supplying tissues.

## Roundabout theory

I advocate a slightly different vascular understanding, which for the sake of simplicity I shall call the *roundabout theory*.[1] In my experience, many patients present the next day, meaning they're possibly presenting as a consequence of venous compression rather than embolism. Imagine the capillaries going into a small pressure system and the veins exiting the other side - if you block the veins, then nothing can go in on the arterial side. If we look at a small filler bolus, it's usually carried downstream by blood flow, and that's the classic embolism. That's the sort of thing that we see for example in the labial artery. There's no collateral circulation and if you damage the artery on the way in, then you're going to cause a problem.

## Reversal protocol for retinal vascular occlusion

Whenever a large filler bolus embolises a vessel, the consequence is retrograde flow to the blood's normal direction, in a distal segment whenever the pressure is taken off the syringe. If you inject the temporal area, you can end up with an obvious area of blanching, or at worse retinal vascular occlusion (VO), and consequently unilateral blindness occurring within a short time. Are you confident you know what to do if this happens to you?

First, don't panic. You must obviously discontinue the injection if it's happening in front of your eyes. The first evidence of necrosis is pain, and this happens even before blanching. Next, massage the area and use heat packs on the area, both as a means of dispersal and vasodilation. It's most important to understand exactly why it has happened and in my mind to establish whether it's arterial or venous. Is it reversible or not? If it's hyaluronic acid, you must use Hyalase (Hyaluronidase).
I do this slightly differently to other physicians and originally advocated the use of much higher doses of hyalase in the region 350iu to 750 iu. These higher doses were accepted at the Consensus Recommendation on Hyalase in Las Vegas 2015.[2] I mix Hyalase with bacteriostatic saline and lignocaine. This is because Hyalase burns like an acid when mixed with normal saline. If you add lidocaine - *and notice I'm saying lidocaine, not lidocaine-adrenaline* - lidocaine will widen the embolised vessels. With the Hyalase - there are 1,500 units in the ampoule and I add 1ml of bacteriostatic saline, because it's buffered so it's not going to hurt the patient. I then draw out 0.2 ml - that's 300 units of Hyalase. I then mix the same amount with 2% lidocaine, and each 0.1ml of that delivers a controllable 75 units. Use as much as you have to, to save the patient's face and inject in many different areas along the area of reticulation. Use up to 750 units twice daily or 375 units four times daily for smaller problems. I would even advocate the supraorbital use of Hyalase in the case of impending blindness.

**Always check to see if a patient is allergic to hyaluronidase by doing a skin prick saline comparison test with hyalase before treatment.**

## Venous problems

If it is considered venous, my way of treating the problem is also very different. In a case presenting the next day, I give 10mg of dexamethasone IV stat as a bolus. This will be unproblematic because it will reduce the gross inflammatory response secondary to necrosis, even if it's arterial. Note also that hyaluronic acid, absorbs water when it goes into the skin, and consequently increases in size by three to four times, so you're going to reduce that oedema also.

## Using vasodilatories

Everybody says to use topical nitrates, but in my experience, there are issues with this. Firstly, you can't use them during the night-time because the patient's asleep and it requires hourly application; plus, they're very messy. I advocate the use of other vasodilatory nitrates which are more long-lasting and easier to find, especially Viagra®, Cialis® and Levitra®. This may sound unconventional, but I consider any sort of drugs that we use for erectile dysfunction are perfect for this. They're going to cause vasodilation, in the same way as the other nitrates by increasing GMP, smooth muscle action. Consequently, we get vasodilation.

## Hyperbaric oxygen (HBO) therapy

Hyperbaric oxygen (HBO) therapy uses intermittent breathing of 100% oxygen at pressures >1 atmosphere absolute (ATA). The therapeutic effect of HBO is attributable to the mechanical effect of increased environmental pressure on gas-containing spaces in the body and the physiologic changes induced by hyperoxia. The inspiration of high levels of oxygen has a negligible impact on the total haemoglobin oxygen content. However, HBO increases the amount of oxygen dissolved in plasma, from 0.32 to 6 mL O2/100 mL of blood when breathing 100% O2 at 3 ATA. This considerable increase in the amount of oxygen made available to the tissues is of great importance when tissue oxygenation is impaired. The emergent treatment of occlusive vascular disease of the facial artery or the retina nowadays is HBO therapy given early for eligible patients.[3, 4] HBO therapies can be found in most European large towns and is not a very expensive means of treatment (costing about €50/hour).

## Special note on retinal artery occlusion

The supraorbital origin is closer to the retinal artery origin from the ophthalmic artery (than the supratrochlear artery) and the notch is palpable as an identifiable landmark. Cadaver studies have shown that the supraorbital and supratrochlear arteries are capable of being cannulated and supported this approach to retinal artery occlusion. This notch and the surrounding area of the supraorbital and supratrochlear arteries on the forehead easily could give us a potential site of reversal for introduction of Hyalase, rather than by direct retrobulbar or intra-orbital injection.

## Supraorbital notch

The supraorbital notch is best located by running a finger along the underside of the superior orbital rim from the supero-medial aspect of the orbit and pushing superiorly as the finger is slowly moved laterally until a depression is located. Injection should be aimed into the notch from above and directed toward the origin of the artery, toward the eye. It must be timely because the eye has very limited ability to withstand ischemia. With so many new injectors who may not have a complete knowledge of the underlying facial anatomy, these simple landmarks may help their management of these complications.

## Wound healing after VO

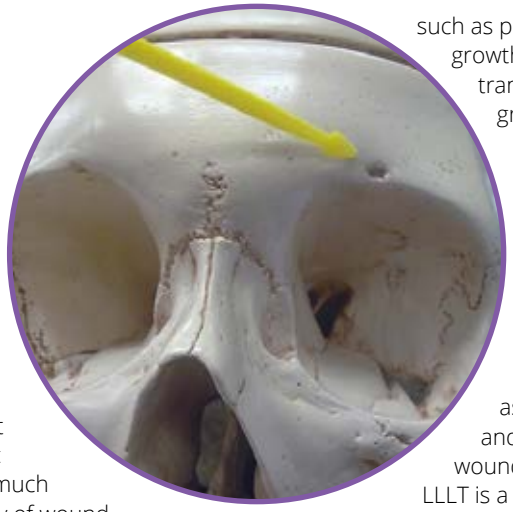

Wound healing, especially impending skin necrosis is a subject of great interest and involvement for the aesthetic industry. While much of the physiology of wound healing is understood, gaps still exist in our understanding of the phenomenon, especially epithelial formation to prevent dermal scarring. Vascular occlusion complications (like burns) have an absence of blood and fibronectin to stimulate epithelial tissue and dermal scars are inevitable. We require secondary mechanisms of action to provide epithelium to these injuries. We can cause fibroblast proliferation and neocollagenesis by the use 633nm low level laser light (LLLT) and growth factors from platelet rich plasma (PRP). The (LLLT) probably reverses mesenchymal stem cells to produce new epithelium. The use of PRP into the wound provides signal messengers and growth factors and may result in unwanted angiogenesis due to vascular endothelial growth factor (VEGF), a signal protein produced by cells that stimulates the formation of blood vessels. This effect may be modified later using Intense Pulsed Light (IPL) when new epithelium has regrown. There is growing evidence from recent Chinese studies that mesenchymal stem cells can be converted back into epithelial tissue by the use of 633 nm light.[5]

minimarnett/Flickr

### Re-epithelisation: PRP & LLLT

PRP can regenerate tissue regeneration and it is becoming a valuable adjunct to promote healing in many procedures in aesthetic medicine. PRP derives from the centrifugation of the patient's own blood and it contains growth factors that influence wound healing, thereby playing an important role in tissue repairing mechanisms. Platelets form a rich source of important growth factors, such as platelet-derived growth factor (PDGF), transforming growth factor-b (TGF-b) 1 and 2, and vascular endothelial growth factor (VEGF); all of these are involved in the angiogenic cascade which assists in hard and soft tissue wound healing.

LLLT is a fast-growing technology used to treat a multitude of conditions that require stimulation of healing, relief of pain and inflammation, and restoration of function. The photons are absorbed by mitochondrial chromophores in skin cells. Consequently, electron transport, adenosine triphosphate (ATP) nitric oxide release, blood flow, reactive oxygen species increase, and diverse signalling pathways get activated. Stem cells can be activated allowing increased tissue repair and healing.[6, 7, 8]

### Use of the HELPIR

HELPIR is an acronym for a technique used to treat wounds caused by dermal filler vascular occlusion that may lead to extensive scarring. It combines most of the techniques mentioned above; This includes HBO. Mild exfoliation may later be used - 2% Salicylic Acid, 0.3% Retinol etc. - to treat partially undifferentiated epithelial tissue. Devices used include: Lumenis Quantum IPL, Omnilux Revive 633, Genosys Omega Light, Lumenis Ultralase CO2 Laser with ActiveFx.

## Summary

To summarise the reversal protocol: discontinue immediately, massage the affected area, apply warm packs, bolus the dexamethasone, mix the hyaluronidase - don't be afraid to use it - and consider the use of Viagra or Cialis. However, care should be taken when considering the use of topical nitrates as it is now advocated to close down anastomotic networks and can also cause syncopal episodes.

If you're a doctor who uses fillers, I would consider it essential to not only carry hyaluronidase in your fridge and be very familiar with your reversal protocol, but to be aware of which of your colleagues you could approach for assistance, should the need arise. It could save your patient's face.

## References


1. Dr. Patrick Treacy introduces the roundabout; theory of dermal filler induced vascular occlusion - Body Language, December 2015.
2. Treatment of Hyaluronic Acid Filler-Induced Impending Necrosis With Hyaluronidase: Consensus Recommendations. Cohen JL, Biesman BS, Dayan SH, DeLorenzi C, Lambros VS, Nestor MS, Sadick N, Sykes J. Aesthet Surg J. 2015 Sep;35(7):844-9.
3. Hyperbaric oxygen and wound healing Sourabh Bhutani and Guruswamy Vishwanath
4. Hyperbaric oxygen therapy for chronic wounds. Kranke P, Bennett MH, Martyn-St James M, Schnabel A, Debus SE, Weibel S.
5. Visible red light enhances physiological anagen entry in vivo and has direct and indirect stimulative effects in vitro. Sheen YS, Fan SM, Chan CC, Wu YF, Jee SH, Lin SJ.
6. Autologous platelet-rich plasma for treating chronic wounds. Martinez-Zapata MJ et al Cochrane Database Syst Rev. 2016 May 25
7. Platelet-rich plasma (PRP) in dental and oral surgery: from the wound healing to bone regeneration. Albanese A, Licata ME, Polizzi B, Campisi G. Immun Ageing. 2013; 10: 23.
8. Low-level laser (light) therapy (LLLT) in skin: stimulating, healing, restoring. Avci P, Gupta A, Sadasivam M, Vecchio D, Pam Z, Pam N, Hamblin MR. Semin Cutan Med Surg. 2013 Mar;32(1):41-52.

CPD CERTIFIED
The CPD Certification Service

The content of the following has been certified by the CPD Certification Service as conforming to continuing professional development principles.

Article: Would you know what to do with an adverse event? Dr. Patrick Treacy discusses addressing dermal filler complications

CONSULTINGROOM.COM (1376)

Date: March 2018 Certificate No: A010377

**To download a CPD Reflective Learning Form, produced in association with the British Association of Cosmetic Nurses (BACN), please use the QR code or visit bit.ly/CR-CPD in your web browser.**